

Review Article

Can Apoptosis Explain Heart Failure?

Dinender Kumar¹, Thangirala Sudha², Pawan K Singal²¹Cardiovascular Research Centre, Department of Medicine, University of Wisconsin, Madison, WI, USA²Institute of Cardiovascular Sciences, St. Boniface General Hospital Research Centre and Department of Physiology, Faculty of Medicine, University of Manitoba, Winnipeg, Canada

Kuwait Medical Journal 2003, 35 (2): 86-90

ABSTRACT

The presence of cardiac myocyte apoptosis has been reported in a variety of cardiovascular conditions including ischemia-reperfusion, myocardial infarction, end-stage heart failure, and adriamycin cardiomyopathy. However, the significance of myocyte apoptosis in cardiac pathophysiology is not clearly established and requires further investigation. The major controversy is due to the lack of sensitivity and specificity of different methods used for the detection of apoptosis. A high variability in the apoptotic cell count reported in the literature has also been an issue. TUNEL assay used for the detection and count of myocyte

apoptosis does not solely identify apoptotic nuclei. Furthermore, myocytes being mononuclear or binuclear, the significance of one nucleus and/or a certain percentage of fragmented nuclei being TUNEL-positive is unclear. Whether the 'early stage' apoptosis is reversible or irreversible is also unresolved. There is now consensus that apoptosis is an important biological process and it does occur in the heart. At present, a complete understanding of its clinical significance in different cardiac conditions remains to be established but it can be viewed as one of the contributing factors in the pathogenesis of heart failure.

KEY WORDS: apoptosis, caspases, heart, mitochondria

INTRODUCTION

Myocardial cell loss in the heart due to apoptosis or necrosis is considered to play an integral role in the development of heart pathophysiologies including ischemia-reperfusion injury, acute and chronic myocardial infarction and adriamycin cardiomyopathy^[1,2,3]. This review will focus on the occurrence as well as probable role of apoptosis in heart failure. The main physiological advantage of apoptotic cell death in injured tissue is that it avoids the indiscriminate activation of the immune response, which is normally associated with necrosis. Morphologically, the characteristic features of apoptosis are: formation of membrane blebbing, chromatin condensation which is reflected as the "half moon" or "horse-shoe" appearance of the nucleus, nucleosomal DNA fragmentation and formation of apoptotic bodies^[4,5]. These apoptotic bodies consist of cellular organelles, fragments of nucleus and mitochondria and are easily phagocytosed by neighboring cells and eventually degraded inside the cell^[6]. Myocyte apoptosis in the heart has been described morphologically in experimental heart failure as well as hibernating myocardium^[7].

Apoptosis vs Necrosis

Apoptosis and necrosis are recognized as two independent mechanisms leading to myocyte cell death, in various heart diseases. The major biochemical and morphological differences between the two types of cell death have been reported in an excellent review by Majno and Joris^[8]. Apoptosis is a genetically controlled event whereas necrosis is a form of accidental cell death results from cellular injury^[8]. Apoptotic process induced by various stimuli involves nuclear chromatin condensation, formation of DNA fragments of 180-200 base pairs and cell shrinkage. Necrosis is characterized by cell swelling, dense chromatin appearing as clumps and random fragmentation of DNA^[8]. There is no inflammatory response observed in apoptosis whereas an inflammatory response is present in the necrotic process^[8].

Apoptosis in Heart Failure

Acute myocardial infarction (AMI) is the major cause of morbidity and mortality due to heart diseases. It is widely accepted that prolonged period of myocardial ischemia and reperfusion cause tissues injury and myocyte cell death^[9,10]. Apoptosis has been confirmed in infarcted border

Address correspondence to:

Dr. Pawan K. Singal, Institute for Cardiovascular Sciences, St. Boniface General Hospital Research Centre, 351 Tache Avenue, Room R3022, Winnipeg, Manitoba, Canada R2H 2A6. Tel: (204) 235-3416; Fax: (204) 233-6723

and non-infarcted zones^[11]. The percentage of apoptotic cells in the border zone were significantly higher compared to remote non-infarcted zone and the control patients^[11]. Post-mortem tissue samples obtained from 20 AMI patients who died within 10 days from the onset of symptoms showed 12% of the apoptotic myocyte population in the zone bordering the infarct and approximately 1% in the non-infarcted region^[12]. These findings suggest that AMI has the high prevalence of myocyte apoptosis in the peri-infarct border zone in comparison with non-infarcted area. Apoptosis and necrosis were also observed in autopsy and explant myocardial infarction cases at 12 hours to two weeks. Apoptosis in these hearts was noticed in early stages of myocardial infarction and none was found from five days to two weeks^[13]. Myocardial infarcted rats' hearts showed 2.7 million myocyte apoptotic nuclei at two hours and the number increased to 6.6 million after 4.5 hours of infarction in left ventricular free wall and persisted for seven days^[14]. Several other animal studies confirmed that apoptosis is predominantly present in infarcted heart compared to necrosis^[15].

End-stage heart failure patients with NYHA IV classification, showed myocyte apoptosis using TUNEL assay as well as DNA ladder^[16]. Similarly, apoptosis was present in ischemic and dilated cardiomyopathies^[17-21]. Acute myocardial infarction in humans was associated with significant apoptosis in the zone of recent infarction compared to remote non-infarcted zone^[22]. Recently Kanoh et al examined 20 patients with dilated cardiomyopathy and 20 normal controls for apoptosis using standard TUNEL-assay and EM-TUNEL using immunogold^[18]. TUNEL staining showed 15% of apoptotic nuclei in dilated cardiomyopathy compared to 0% in normal controls and EM-TUNEL showed neither apoptosis nor necrosis but it stained living cells going through DNA repair mechanism^[18]. Myocyte apoptosis was also observed in progressive heart failure in mice and rats after left coronary artery ligation^[23,24]. Apoptosis was significantly increased up to 12 weeks at the border zone whereas decreased trend of apoptosis was observed thereafter in rats^[23].

Adriamycin (doxorubicin) is an effective antitumor drug used for the treatment of cancer patients. The use of this drug is limited because of the risk of cardiomyopathy leading to congestive heart failure^[25]. Adriamycin-induced cardiomyopathy is a complex entity and involves cellular morphological changes such as dilatation of the sarcoplasmic reticulum, loss of myofibrils, and ultimately emptying of the myocyte with a minimal immune response^[25]. In vitro exposure to

adriamycin and daunorubicin resulted in TUNEL-positive apoptosis in adult and neonatal rat heart myocytes^[5,26]. Adriamycin-induced cardiomyopathy in rats was associated with apoptotic nuclei at 4, 10, 16 and 21 days^[2]. A biphasic response was seen where apoptosis peaked at 4 and 21 days post-treatment^[2]. Apoptosis in this model was confirmed by TUNEL assay as well as by the increased expression of BAX/Bcl-2 ratio^[2]. Such a pattern of apoptosis in this study was indicative of an apoptotic time window. Recent study shows that apoptosis is present in doxorubicin treated rats and it is caused by mitochondrial release of cytochrome c and further activation of caspase-3^[27]. These studies suggest that apoptosis is evidently present in the adriamycin-induced cardiomyopathy, leading to congestive heart failure. These apoptotic changes as well as heart failure were prevented by the use of antioxidant probucol, suggesting some role of oxidative stress.

Regulation of Myocardial Apoptosis

Regulation of myocardial apoptosis in heart diseases is found to be multifactorial and complex (Fig. 1). The wide variety of proapoptotic stimuli are triggered under disease conditions such as ischemia-reperfusion, myocardial infarction and adriamycin cardiomyopathy. The possible molecular changes under these settings include oxidative stress, angiotensin II, mitochondrial dysfunction, TNF- and other intrinsic factors^[1]. The balance between apoptotic triggered pathways and antiapoptotic protein activation determines the

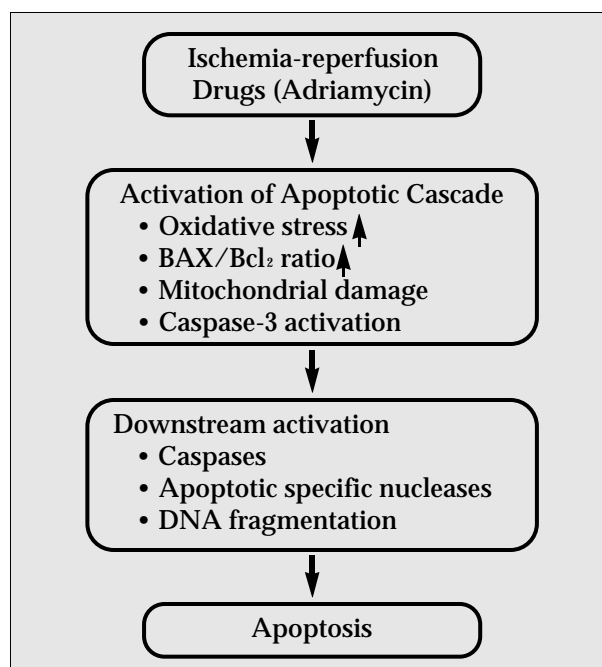


Fig. 1: Schematic representation of apoptotic stimuli and downstream pathways

fate of the cell i.e., death or survival. After initiation, the regulation of apoptotic machinery is complex and in general divides into three different phases (initiation phase, intermediate phase and execution phase) on the basis of alterations of cellular, morphological and biochemical events. The initiation phase shows the early signs of membrane blebbing and is observed in cardiomyocyte cell culture after adriamycin exposure^[5]. This phase generally gives way to the intermediate phase, which involves change in proapoptotic proteins, BAX/Bcl2 ratio, mitochondrial alterations, the release of cytochrome c and activation of caspases^[9,28]. The final stage of apoptosis involves further activation of downstream caspases and inactivation of poly ADP-ribose polymerase (PARP), which eventually leads to DNA fragmentation^[1,5,28] and formation of apoptotic bodies. These three phases of apoptosis have been characterized by ultra and light microscopy as well as using biochemical assays.

These myocyte apoptotic process can be inhibited at any step thus inhibiting apoptotic cell death and/or sustain myocyte cell survival. For example, inhibition of this process at the initiation phase using various antioxidants^[1], probucol^[2], beta-blockers (carvedilol)^[29], angiotensin converting enzyme inhibitor^[30], AT receptor blockers^[11,30], may prevent the cell death by inhibiting the turn on of apoptotic machinery. At the intermediate phase level apoptosis may be reversed by up-regulation of Bcl-2 and caspase-3 inhibitor blockers^[31]. Execution phase can be inhibited by upregulation of HSP-70 or other downstream caspase inhibitors and may prolong the cell survival but at this step it is difficult to reverse this apoptotic process completely.

Biochemical features of apoptosis

The appearance of phosphatidylserine (PS) on the outer surface of apoptotic cell plasma membrane is recognized as an early sign of apoptosis^[6,32]. The translocation of PS was identified by light microscopy with annexin V staining. Both oxidative stress and calcium overload can also result in externalization of this PS^[33,34]. The DNA fragments formed by endogenous DNases, generate blunt ends and single strand 3' overhangs^[6]. DNA fragments are detected using gel electrophoresis as a ladder pattern of 180-200 bp, as well as at the microscopic level by terminal transferase mediated DNA nick-end labeling (TUNEL)^[1,5].

Limitations of the Techniques and the Big Confusion

The increasing interest in apoptosis and its role in the progression of heart failure is intriguing for cardiovascular basic scientists and clinicians.

However, the topic of apoptosis is surrounded by various questions about the reliability of the apoptotic myocyte cell count due to limitations of small sample size and to sensitivity and specificity of apoptotic detection techniques. Most of the quantitative and qualitative reports on apoptosis in various heart diseases are based on three different techniques, such as the TUNEL assay, the DNA ladder and electron microscopy^[1]. These techniques used to detect myocyte apoptosis on the basis of solely DNA fragmentation are not satisfactory for providing a clear picture of the quantitative apoptotic cell count.

1. TUNEL assay identifies single strand DNA breaks as well as double strand DNA breaks with free 3'-OH termini. The use of TUNEL assay has become questionable as it also detects cells that undergo necrosis and normal myocytes going through natural cellular DNA repair^[18]. Moreover, the criteria used to measure percentage of apoptotic myocyte cell death vary between investigators. For an exact quantification of apoptotic myocyte, the endothelial or fibroblast cell populations detected by TUNEL assay is also a limitation. To overcome this problem in heart tissue, TUNEL assay should be co-stained with cell specific cytoplasmic proteins such as myosin or -actinin for cardiomyocytes, vimentin for endothelial cells and fibronectin for fibroblasts.
2. The DNA ladder is another commonly used method for the detection and identification of apoptosis both *in vivo* and *in vitro*^[1,2,7]. The use of this method is also limited, as DNA isolation required to test this assay is adequate for *in vitro* studies but DNA isolation from heart tissue involves other cell populations present. For example, DNAgels available from cardiomyocytes (ischemic and adriamycin) show a mixture of DNA ladder and smear, indicative of apoptosis and necrosis respectively^[5].
3. Electron microscopy is used to detect apoptosis on the basis of chromatin condensation, apoptotic bodies and nuclear fragmentation^[1]. Electron microscopy is certainly a highly sensitive method to detect apoptosis but it is a very laborious qualitative technique and the tissue sample used is very small (1 mm²) compared to that examined by the TUNEL assay (5 mm). This assay cannot be used for quantitative purposes. We suggest that for more reliable information, the use of TUNEL-assay or DNA laddering for the identification of apoptosis should always be combined with additional evidence of apoptosis such as up-regulation of pro- or anti-apoptotic gene products and/or morphological criteria.

Because of the technical difficulties listed above, the reported apoptotic index in heart diseases is highly variable. For example: 8% in ventricular hypertrophy^[35], 5-35% in end stage heart failure patients due to idiopathic dilated cardiomyopathy and ischemic heart disease^[16], 0.24% in end stage heart failure patients due to ischemic cardiomyopathy, .05-8.9% in biopsies taken from ischemic cardiomyopathy patients^[19,11]. With apoptosis as high as 35%, the heart should disappear in a short time span. Moreover, inhibition of apoptosis by various pharmacological agents has been shown but without any decrease in infarct size and or improvement in cardiac functions^[36]. Future studies are required to examine myocyte apoptosis cell count using combination of two markers, e.g. TUNEL-staining should be co-localized with caspase-3 or bax staining.

CONCLUSIONS

Experimental and human studies suggest that apoptosis is present in many cardiac diseases and may be an important biological phenomenon causing cell loss in the heart. However, techniques used for the estimation of apoptosis cell count are surrounded by number of pitfalls. It appears that apoptosis may be one of the many factors involved in myocardial dysfunction and may not be the sole player responsible for the pathogenesis of heart failure.

ACKNOWLEDGEMENTS

The work reported in this paper was supported by a grant from the CIHR.

REFERENCES

- Kumar D, Lou H, Singal PK. Oxidative stress and apoptosis in heart dysfunction. *Herz* 2002; 27:662-668.
- Kumar D, Kirshenbaum LA, Li T, Danelisen I, Singal PK. Apoptosis in adriamycin cardiomyopathy and its modulation by probucol. *Antioxid Redox Signal* 2001; 3:135-145.
- Gottlieb RA, Bursleson KO, Kloner RA, Babior BM, Engler RL. Reperfusion injury induces apoptosis in rabbit cardiomyocytes. *J Clin Invest* 1994; 94:1621-1628.
- Laguens RP, Meckert PM, Martino JS, Perrone S, Favaloro R. Identification of programmed cell death (apoptosis) *in situ* by means of specific labeling of nuclear DNA fragments in heart biopsy samples during acute rejection episodes. *J Heart Lung Transplant* 1996; 15:911-918.
- Kumar D, Kirshenbaum L, Li T, Danelisen I, Singal P. Apoptosis in isolated adult cardiomyocytes exposed to adriamycin. *Ann N Y Acad Sci* 1999; 874:156-168.
- Kerr JF, Wyllie AH, Currie AR: Apoptosis: a basic biological phenomenon with wide-ranging implications in tissue kinetics. *Br J Cancer* 1972; 26:239-257.
- Haunstetter A, Izumo S. Apoptosis: basic mechanisms and implications for cardiovascular disease. *Circ Res* 1998; 82:1111-1129.
- Majno G, Joris I. Apoptosis, oncosis, and necrosis. *An overview of cell death. Am J Pathol* 1995; 146:3-15.
- Fliss H, Gattinger D. Apoptosis in ischemic and reperfused rat myocardium. *Circ Res* 1996; 79:949-1056.
- Moudgil R, Menon V, Xu Y, Musat-Marcu S, Kumar D, Jugdutt BI. Postischemic apoptosis and functional recovery after angiotensin II type 1 receptor blockade in isolated working rat hearts. *J Hypertens* 2001; 19:1121-1129
- Saraste A, Pulkki K, Kallajoki M, Henriksen K, Parvinen M, Voipio-Pulkki L-M. Apoptosis in human acute myocardial infarction. *Circulation* 1997; 95:320-323.
- Olivetti G, Quaini F, Sala R *et al.* Acute myocardial infarction in humans is associated with activation of programmed myocyte cell death in the surviving portion of the heart. *J Mol Cell Cardiol* 1996; 28:2005-2016.
- Veinot JP, Gattinger DA, Fliss H. Early apoptosis in human myocardial infarcts. *Human Pathol* 1997; 28:485-492.
- Kajstura J, Cheng W, Reiss K *et al.* Apoptotic and necrotic myocyte cell deaths are independent contributing variables of infarct size in rats. *Lab Invest* 1996; 74:86-107.
- Anversa P, Cheng W, Liu Y, Leri A, Redaelli G, Kajstura J. Apoptosis and myocardial infarction. *Basic Res Cardiol* 1998; 93:8-12.
- Narula J, Haider N, Virmani R *et al.* Apoptosis in myocytes in end-stage heart failure. *N Engl J Med* 1996; 335:1182-1189.
- Olivetti G, Abbi R, Quaini F *et al.* Apoptosis in the failing human heart. *N Engl J Med* 1997; 336:1131-1141.
- Kanoh M, Takemura G, Misao J *et al.* Significance of myocytes with positive DNA *in situ* nick end-labeling (TUNEL) in hearts with dilated cardiomyopathy: not apoptosis but DNA repair. *Circulation* 1999; 99:2757-2764.
- Latif N, Khan MA, Birks E, O'Farrell A, Westbrook J, Dunn MJ, Yacoub MH. Upregulation of the Bcl-2 family of proteins in end stage heart failure. *J Am Coll Cardiol* 2000; 35:1769-1777.
- Saraste A, Voipio-Pulkki LM, Heikkila P, Laine P, Nieminen MS, Pulkki K. Soluble tumor necrosis factor receptor levels identify a subgroup of heart failure patients with increased cardiomyocyte apoptosis. *Clin Chim Acta* 2002; 320:65-67.
- Song H, Conte JV Jr, Foster AH, McLaughlin JS, Wei C. Increased p53 protein expression in human failing myocardium. *J Heart Lung Transplant* 1999; 18:744-749.
- Baldi A, Abbate A, Bussani R *et al.* Apoptosis and post-infarction left ventricular remodeling. *J Mol Cell Cardiol* 2002; 34:165-174.
- Palojoki E, Saraste A, Eriksson A *et al.* Cardiomyocyte apoptosis and ventricular remodeling after myocardial infarction in rats. *Am J Physiol Heart Circ Physiol* 2002; 280:2726-2731.
- Sam F, Sawyer DB, Chang DL *et al.* Progressive left ventricular remodeling and apoptosis late after myocardial infarction in mouse heart. *Am J Physiol Heart Circ Physiol* 2000; 279:422-428.
- Singal PK, Iliskovic N, Li T, Kumar D. Adriamycin cardiomyopathy: pathophysiology and prevention. *FASEB J* 1997; 11:931-936.
- Arola OJ, Saraste A, Pulkki K, Kallajoki M, Parvinen M, Voipio-Pulkki LM. Acute doxorubicin cardiotoxicity involves cardiomyocyte apoptosis. *Cancer Res* 2000; 60:1789-1792.
- Childs AC, Phaneuf SL, Dirks AJ, Phillips T, Leeuwenburgh C. Doxorubicin treatment *in vivo* causes cytochrome C release and cardiomyocyte apoptosis, as well as increased mitochondrial efficiency, superoxide dismutase activity, and Bcl-2:Bax ratio. *Cancer Res* 2002; 62:4592-4598.
- Narula J, Pandey P, Arbustini E *et al.* Apoptosis in heart failure: release of cytochrome c from mitochondria and activation of caspase-3 in human cardiomyopathy. *Proc*

- Natl Acad Sci USA 1999; 96:8144-8149.
29. Yue TL, Ma XL, Wang X *et al*. Possible involvement of stress-activated protein kinase signaling pathway and Fas receptor expression in prevention of ischemia/reperfusion-induced cardiomyocyte apoptosis by carvedilol. *Circ Res* 1998; 82:166-174.
 30. Jugdutt BI, Kumar D. Angiotensin II and cardiomyocyte apoptosis in the SHR. *Inter J Cardiology* 2001; 81:129-130.
 31. Chen Z, Chua CC, Ho YS, Hamdy RC, Chua BH. Overexpression of Bcl-2 attenuates apoptosis and protects against myocardial I/R injury in transgenic mice. *Am J Physiol Heart Circ Physiol* 2001; 280:2313-2320.
 32. Van Heerde WL, Robert-Offerman S, Dumont E *et al*. Markers of apoptosis in cardiovascular tissues: focus on Annexin V. *Cardiovasc Res* 2000; 45:549-559.
 33. Bevers EM, Comfurius P, Dekkers DW, Harmsma M, Zwaal RF. Transmembrane phospholipid distribution in blood cells: control mechanisms and pathophysiological significance. *Biol Chem* 1998; 379:973-986.
 34. Kagan VE, Fabisiak JP, Shvedova AA, Tyurina YY, Tyurin VA, Schor NF, Kawai K. Oxidative signaling pathway for externalization of plasma membrane phosphatidylserine during apoptosis. *FEBS Lett* 2000; 477:1-7.
 35. Matturri L, Milei J, Grana DR, Lavezzi AM. Characterization of myocardial hypertrophy by DNA content, PCNA expression and apoptotic index. *Int J Cardiol* 2002; 82:33-39.
 36. Okamura T, Miura T, Takemura G *et al*. Effect of caspase inhibitors on myocardial infarct size and myocyte DNA fragmentation in the ischemia-reperfused rat heart. *Cardiovasc Res* 2000; 45:642-650.