

Case Report

A New Approach for the Treatment of Large Epiglottic Cysts using Nasoendoscopes

Pradeep Shenoy, Sohail Abdul Malik, Rashid Al Duwillah
Department of ENT surgery, Armed Forces Hospital, Kuwait

Kuwait Medical Journal 2007, 39 (1): 59-61

ABSTRACT

We report two cases of epiglottic cysts with their clinical presentation, radiological and histological aspects. Naso-

endoscopes of zero and thirty degrees were used as a new technique for the excision of these epiglottic cysts.

KEY WORDS: debulking, epiglottic cysts, excision, nasoendoscope

INTRODUCTION

Epiglottic cysts are a rare entity but may present as an acute emergency in both children and adults if it compromises the airway. Therefore, it should be kept in mind in the differential diagnosis of stridor or difficulty in breathing. Common treatment modalities in dealing with these epiglottic cysts are endoscopic excision, aspiration, marsupialization and even external approaches through the neck in cases of very large epiglottic cysts. Here, we report our use of a nasoendoscope for their proper visualization and complete excision.

CASE - 1

A 26-years old man presented with muffled voice for the past one and half year. Throat examination revealed a large cystic mass behind the posterior end of the base of the tongue. Indirect laryngoscope unveiled its position, being mainly in the left vallecula and extending towards the lingual surface of the epiglottis and medial half of the right vallecula. A fiberoptic examination (Fig. 1), X - ray soft tissue of the neck (Fig. 2) and CT scan of the neck further confirmed the credibility of the above findings (Fig. 3).

Operatively, fiberoptic naso-tracheal intubation was done and a long blade Boyle - Davis mouth gag was passed to visualize the cyst. Zero and thirty-degree Hopkins nasoendoscope was used to locate the pedicle, which was then grasped with long curved forceps and excised using bipolar cautery. The histopathology confirmed an epithelial epiglottic cyst.

CASE - 2

A muffled voice accompanied by mild dysphagia for a period of four months drew a 33-years old man to the ENT OPD. An indirect laryngoscope exposed a large cystic swelling extending from the left side of the base of the tongue to the lingual surface of the epiglottis. A CT scan of the neck correlated with clinical findings. A similar procedure as mentioned above was performed in addition to aspiration of the large cyst using a wide bore needle to debulk the cyst and to get an access around the cyst (Fig. 4). The histopathology confirmed an epithelial epiglottic cyst.

DISCUSSION

Epiglottic cysts are virtually clandestine in otorhinolaryngological practice^[1].

They may be congenital or acquired^[2]. Congenital cysts promulgate themselves during early childhood due to obstruction of the larynx with apnea or stridor^[3,4]. In adults, small cysts are asymptomatic whereas large cysts cause mild dysphagia with hoarseness and severe cases profess complete airway obstruction^[5]. Some cysts present as an acute epiglottitis^[6]. Epiglottic cysts are an incidental finding in adults^[7] but when perceptively large, it is mandatory to do a preoperative CT scan^[8] and confirm extension with a preoperative fiberoptic endoscopy.

In the presence of a very large cyst causing airway obstruction, tracheostomy may be performed prior to excision^[5]. Intubation in such a case may be very difficult^[7,9]. Aspiration prior to excision has been described in literature. After discussing the

Address Correspondence to:

Dr. Pradeep Shenoy, DLO, FRCS, Post Box No. 8728, 22058 - Salmiya, Kuwait. Tel: 5623257, Fax: +965 - 5623257

E-Mail: pks_ent@hotmail.com

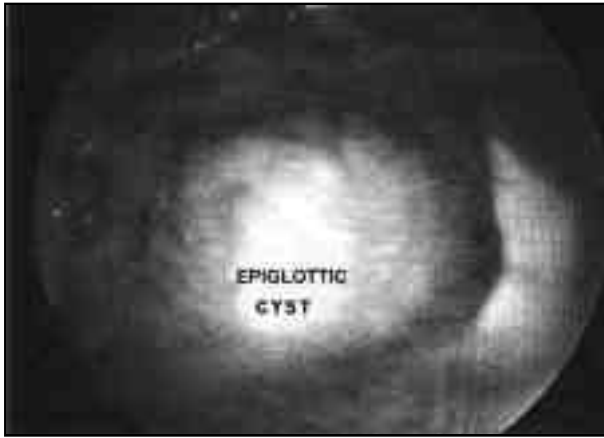

Fig. 1: Fiberoptic examination of epiglottic cyst

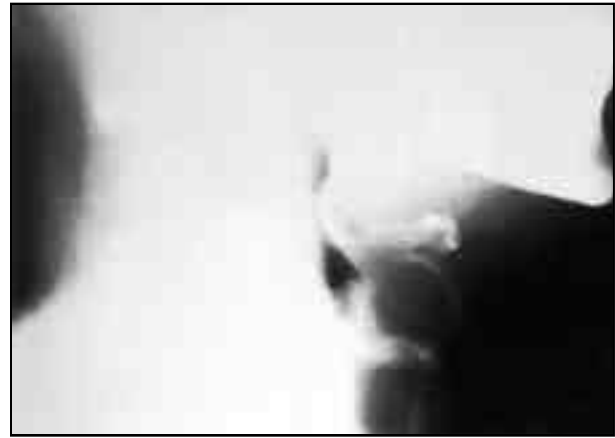

Fig. 2: X-ray soft tissue neck showing epiglottic cyst

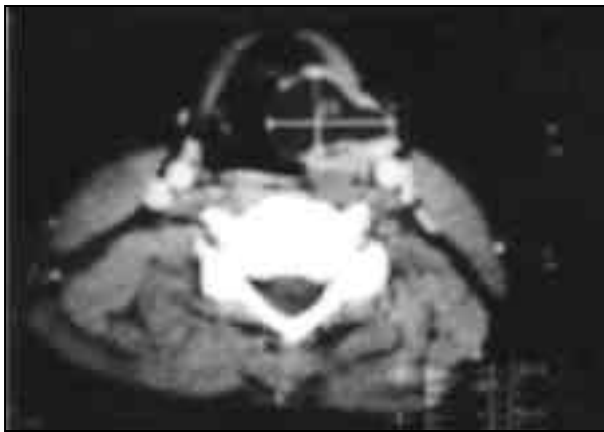


Fig. 3: C.T. scan neck showing epiglottic cyst

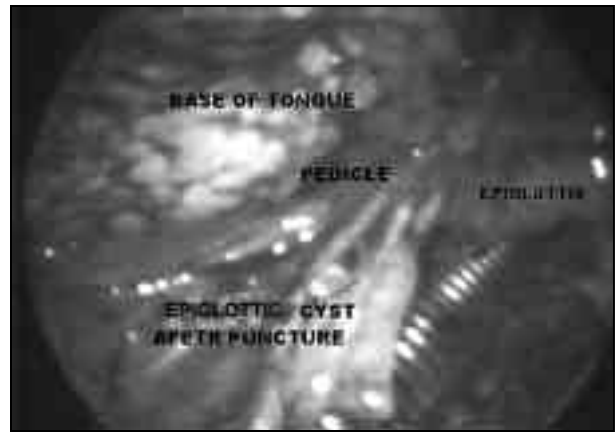


Fig. 4: Epiglottic cyst after aspiration

case with the anesthesiologist, a fiberoptic guided awake nasal intubation is performed^[11]. There are reported cases of deaths during intubation in cases of large cysts^[12]. The cyst appears in the narrow space between lingual surface of the epiglottis and the base of tongue. The exposure of these cysts is very difficult. Surgical treatment of large epiglottic cysts has been described using side - opened laryngoscope and snare^[13]. Boyle - Davis gag with longest tongue blade gives a good access to the epiglottic cyst. Zero and thirty-degree nasoendoscopes give good exposure all around the cyst including its base. Long curved artery forceps are used to grip the base or pedicle and excision is done using cutting diathermy. Suction diathermy is used for the base and oozing spots.

CONCLUSION

Epiglottic cysts are present in an area where accessibility is difficult. The use of zero and thirty-degree nasoendoscopes provide good accessibility and excision could be complete. Since this practice is unparalleled in the literature, we hope it would be laudatory to otolaryngological practice.

ACKNOWLEDGEMENT

Our special thanks to Colonel Ali Ahmed Essa, Director of Armed Forces Hospital, Kuwait, for his kind permission to present the case studies. Our thanks are also due to Mr. C M Khan, Medical Secretary for his secretarial assistance.

REFERENCES

1. Padfield A. Epiglottic cysts. A Case report and review. *Anesthesia* 1972; 27:84-88.
2. Pavlovski VM. Congenital Epiglottic cyst in a three and one-half month old infant. *Pediatrics* 1973; 52:82.
3. Conway EE Jr., Bye MR, Wirtshafer K, et al. Epiglottic Cyst: An unusual cause of stridor in an infant. *Pediatric Emergency Care* 1991; 7:85-86.
4. Dahm MC, Panning B, Lenarz T. Acute apnea caused by an epiglottic cyst. *Int J Pediatr Otorhinolaryngol* 1998; 42:271-276.
5. Henderson LT, Denny JC 3rd, Teichgraeber J. Airway - Obstructing epiglottic cyst. *Annals Otol Rhinol Laryngol* 1985; 94: 473-476.
6. Macneil A, Campbell AM, Clark LJ. Adult acute epiglottitis in association with infection of an epiglottic cyst. *Anaesthesia Intensive Care* 1989; 17:211- 212.
7. Ghabash M, Matta M. An asymptomatic epiglottic mass as a cause of difficult intubation - A case report. *Middle East J*

- Anesth 1994; 12:497-500.
8. Cassleman J, Oyen R, Baert A, *et al.* Computed tomography of infected epiglottic cyst. *J Comput Assist Tomogr* 1986; 10:694-695.
 9. Mason DG, Wark KJ. Unexpected difficult intubation. Asymptomatic epiglottic cysts as a cause of upper airway obstruction during anesthesia. *Anesthesia* 1987; 42:407- 410.
 10. Wijayaweera ND, Ganepala Sr. Epiglottic Cyst aspiration before induction of Anesthesia. *Ceylon Medical Journal* 1993; 38:137- 138.
 11. Gleeson MJ, Siodlak MZ, Wengraf CL. Fibre optic guided nasal intubation - shouldn't we be the experts? *J Laryngol Otol* 1985; 99:775-778.
 12. Jorgenson BK. Epiglottic Cysts as the cause of anesthetic death. *Ugeskr Laeger* 1974; 136:1743-1744.
 13. Kawaida M, Kohno N, Kawasaki Y, *et al.* Surgical treatment of large epiglottic cysts with side-opened direct laryngoscope and snare. *Auris Nasus Larynx* 1992; 19:45-50.