

## Original Article

# A Critical Analysis of the Protocol for the Conservative Treatment of Developmental Dysplasia of the Hip in Kuwait

Milan Rejholec, Hani El-Sisi  
Al-Razi Orthopaedic Hospital, Kuwait

The Kuwait Medical Journal 2001, 33 (1): 48-50

**ABSTRACT**

**Objectives:** To evaluate the results of conservative treatment of developmental dysplasia of the hip to determine which is the most effective treatment in terms of rates of complications as well as from an economical point of view, to prevent unnecessarily long hospital stays.

**Methods:** The results of conservative treatment for developmental dysplasia of the hip are evaluated after an average follow-up of four years in 69 patients and 99 hips (31 bilateral, 23 left side, and 14 right side). All patients were treated at Kuwait's Al-Razi Hospital between January 1995 and December 1996. There were 59 females and 10 males, aged between 5 and 24 months (median: 12 months). The treatment consisted of traction for 1 to 2 weeks followed by manipulation in 36 hips; manipulation with adductor longus tenotomy in 45 hips;

and with adductor longus and psoas tenotomy in 18 hips.

**Results:** Avascular necrosis of the femoral head developed in 16 hips (16%); 14 hips on the affected side and two hips on the unaffected side. Persistent acetabular dysplasia was present in 13 hips, subluxation in nine hips and dislocation in 13 hips. Open reduction was later required in five hips, open reduction and innominate osteotomy in eight hips, and hip extracapsular innominate osteotomy in one hip. The results were evaluated according to the age groups with highest rate of complications after the age of 15 months.

**Conclusion:** The treatment protocol was changed to limit conservative treatment until the age of 14 months. In cases without high dislocation, no traction as preparation for manipulation was used.

KEYWORDS: conservative treatment, developmental dysplasia of the hip

**INTRODUCTION**

Developmental dysplasia of the hip is very frequent in Kuwait. Despite routine screening, there are still more than 40 cases every year of developmental dysplasia of the hip diagnosed after the age of five months. These cases are treated at the Al-Razi Orthopedic Hospital, the only hospital in Kuwait with a pediatric orthopedic unit.

The aim of this retrospective study was to evaluate the results of conservative treatment of developmental dysplasia of the hip in children over the age of five months and to analyze the treatment protocol.

**METHODS**

The study group represented all admitted children to Al-Razi Hospital between 1 January 1995 and 31 December 1996 for the above mentioned diagnosis who went on to complete follow up. The group consisted of 59 female and 10 male children, with 62 bilateral, 23 left side and 14 right side cases of developmental dysplasia of the hip. The average age was 12 months, with range between 5 and 24 months.

Each child was admitted to hospital for one to two week's of overhead traction. The duration of traction depended on the age of the child as well as the clinical and radiological findings. Those in the lower age groups with reducible hips and only mild subluxation were in traction for one week, while the rest were in for two weeks.

Under general anesthesia, possible hip reduction, the cone of stability (also called the safety zone) and tightness of the adductors were tested. In the 36 reducible hips with safety zones between 60 and 90 degrees of abduction and no adductor contracture, only manipulation was used to achieve concentric hip reduction.

In 45 hips with sufficient safety zones between 60 to 90 degrees and tight adductors, open adductor tenotomy was done. Closed tenotomy was abandoned due to the risk of femoral artery injury.

In 18 hips with poor safety zones, open adductor tenotomy was accomplished with psoas tenotomy, which helped to significantly increase the safety zone.

A spica cast was applied in flexion 90 degrees

Address correspondence to:

Dr. Milan Rejholec, MD, PhD, Consultant Orthopedic Surgeon, Al-Razi Orthopedic Hospital, PO Box: 4235, Safat-13043, Kuwait.

and abduction 70 degrees for six weeks when examination under anesthesia was done. Another spica cast was then applied for the same time period after which a broomstick cast was applied for four weeks. A Dennis Brown splint was used during sleeping for a further three months.

Parental compliance was generally good. From a total of 76 patients, 69 completed the entire treatment and reported for follow-ups. All patients were followed, both clinically and radiologically, in the Outpatient Department to evaluate the reduction of the hip, the development of the acetabulum, the need for further surgical treatment, and the occurrence of avascular necrosis. We considered avascular necrosis as an obvious change in the shape of the proximal femoral epiphysis.

These criteria were followed based on the patients' ages at the time of reduction and are the reason why our study group was divided into 10 subgroups (Fig. 1).

**RESULTS**

Persistent acetabular dysplasia was present in 13 hips, subluxation in nine hips and re-dislocation occurred in 13 hips. The highest rate of complication was in the age groups over 14 months (Fig. 2).

Secondary procedures were performed in 15 hips and included open reduction in five hips, open reduction and pelvic osteotomy in eight hips, open reduction and femoral osteotomy in one hip, and extracapsular pelvic osteotomy without opening the joint capsule in one hip.

Avascular necrosis developed in 16 hips, in 14 affected side hips and two unaffected side hips. Of these, seven hips (18.9%) were treated without adductor tenotomy and nine (12.5%) were treated with adductor tenotomy. Avascular necrosis was most frequent (33%) in the 19-20 month age group (Fig. 3).

**DISCUSSION**

Arthrography was not performed as a routine examination as advised by some authors<sup>[2]</sup>. Instead, the cone of stability with concentric reduction on radiograph was considered sufficient. Many authors have discussed traction in the conservative treatment of developmental dysplasia of the hip. Some<sup>[7,9]</sup> support the use of traction before manipulation while others<sup>[6]</sup> find no benefit to traction. From the personal experience of one of the authors<sup>[7]</sup> of this study, traction helps to reduce force during manipulation which, in turn, reduces the risk of avascular necrosis. Avascular necrosis in our study was significantly higher in cases without adductor tenotomy, which can be explained by the greater force required to achieve reduction and by

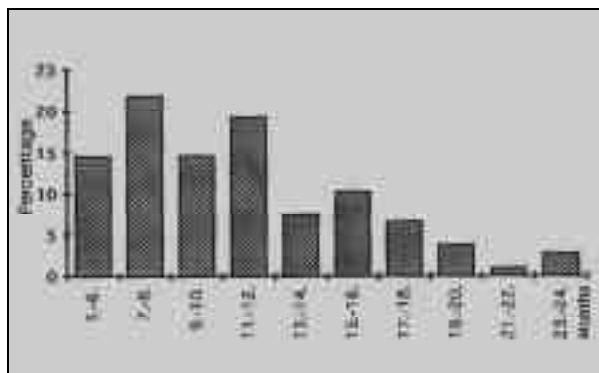


Fig. 1: Percentages of patients according to the age groups in months at the time of manipulation (in months)

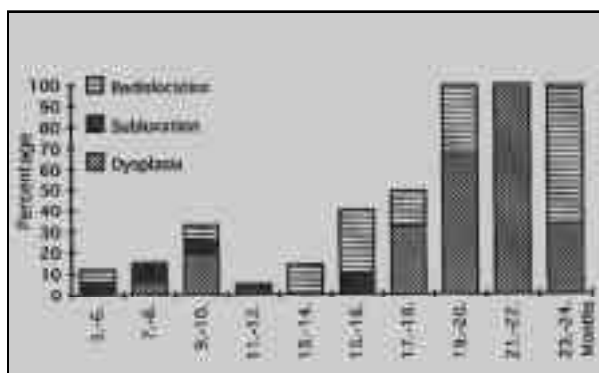


Fig. 2: The occurrence of persistent dysplasia, subluxation and re-dislocation according to the age groups at the time of manipulation

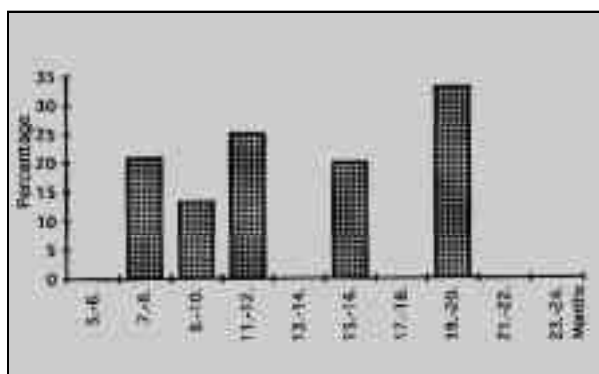


Fig. 3: The incidence of avascular necrosis according to the age groups at the time of manipulation

the return of adductor tightness following general anesthesia. In this study, avascular necrosis in the tenotomy group was virtually the same as that of other authors<sup>[3]</sup> from Middle East, where higher joint laxity plays a significant role. Some authors<sup>[1]</sup> saw signs of avascular necrosis in as many as 50% of cases.

In addition to tenotomy, the position of the spica cast is important. In the present study, two unaffected hips (2%) developed avascular necrosis. Other authors<sup>[5]</sup> have reported a 5% occurrence of avascular necrosis on the unaffected side. This lower incidence can be also explained by generally higher joint laxity in the Middle East. The age factor is obvious (Fig. 3).

Avascular necrosis was diagnosed only if there were obvious changes of proximal femoral epiphysis, classified as number II by Burgos et al<sup>[1]</sup>. The delay of ossification was not considered as avascular necrosis.

Persistent dysplasia, subluxation or re-dislocations were present in 35 hips. After the age of 14 months, the rate was significantly higher (Fig. 2). Similar results are given by others<sup>[4,8]</sup>. In light of the results of this study and the supporting data from the literature, the treatment protocol was changed to limit conservative treatment to the age of 14 months.

## REFERENCES

1. Burgos S, Gonzalez-Herranz P, Ocete G, Rapariz JM. Secondary avascular necrosis after treatment for congenital dislocation of the hip. *J Pediatr Orthop* 1995; 4B:188-193.
2. Fleissner PR Jr, Ciccarelli CJ, Eilert RE, Chang FM, Glancy GL. The success of closed reduction in the treatment of complex developmental dislocation of the hip. *J Pediatr Orthop* 1994; 14:631-635.
3. Gogus MT, Aksoy MC, Atay OA, Acaroglu RE, Surat A. Treatment of congenital dislocation of the hip. Results of closed reduction and immobilization in the hip spica cast. *Turkish J Pediatr* 1997; 39:499-503.
4. Huang SC, Wang JH. A comparative study of nonoperative versus operative treatment of developmental dysplasia of the hip in patients of walking age. *J Pediatr Orthop* 1997; 17:181-188.
5. Malvitz TA, Weinstein SL. Closed reduction for congenital dysplasia of the hip. Functional and radiographic results after an average of thirty years. *J Bone Joint Surg* 1994; 76A:1772-1792.
6. Quinn RH, Renshaw TS, DeLuca PA. Preliminary traction in the treatment of developmental dislocation of the hip. *J Pediatr Orthop* 1994; 14:636-642.
7. Rejholec M, Sosna A, Dupal P. Overhead traction in the treatment of congenital dislocation of the hip. *Chir Organi Mov* 1993; 78:223-226.
8. Schoenecker PL, Dollard PA, Sheridan JJ, Strecker WB. Closed reduction of developmental dislocation of the hips in children older than 18 months. *J Pediatr Orthop* 1995; 15:763-767.
9. Tavares JO, Gottwald DH, Rochelle JR. Guided abduction traction in the treatment of congenital hip dislocation. *J Pediatr Orthop* 1994; 14:643-649.